


PRESENTING CLINICAL SIGNS

DATE History: Grade 2/6 murmur. Episodes of syncope after coughing or activity.

ECHOCARDIOGRAPHIC FINDINGS

2D, M-mode, and Doppler study.

PERFORMED BY:

Loetitia Saint-Jacques, LVT, RVT

Left atrial size is normal. The mitral valve is normal. Left ventricular wall thickness is normal. Left ventricular internal dimensions are normal. Left ventricular systolic function is normal. The aorta and aortic valve appear normal, though there is mildly increased velocity laminar flow velocity in the ascending aorta. Right atrial and right ventricular dimensions are normal. The tricuspid valve is normal. The pulmonary artery and pulmonic valve are normal. No shunting lesions are visualized. No heartworms are visualized. No pericardial effusion or cardiac masses are seen.

INTERPRETED BY

Keith Blass, DVM,
MS, DACVIM
(Cardiology)

ECG: Sinus arrhythmia

LA – 26.6 mm
IVSd – 6.3 mm
LVPWd – 7.2 mm
LVIDd – 26.9 mm
LVIDs – 17.5 mm
FS – 34.9%
RA – 19.2 mm
LVOT – 2.50 m/s
RVOT – 0.94 m/s

PATIENT

Patrick Butler

SPECIES

Canine

ASSESSMENT/RECOMMENDATIONS

Normal echocardiogram and ECG

BREED

Shiba Inu

This examination demonstrates no evidence of structural heart disease. Patrick's murmur appears to be due to the presence of mildly increased flow velocity in his aorta, which is a common reason for a functional/innocent murmur to develop in dogs. Given the absence of abnormalities both in this exam and Patrick's ECG, no reason for his syncopal episodes (or cough) is appreciated, though, given the presence of a sinus arrhythmia, as vasovagal reflex should be considered as a likely differential.

SEX

MI

A Holter and/or event monitor may be warranted for further evaluation of Patrick's syncopal episodes.

AGE

No therapy is recommended based on Patrick's echocardiogram or ECG.

11 mo

A recheck echocardiogram is recommended if the characteristics of Patrick's murmur change, or if other new physical exam and/or clinical abnormalities suggestive of the presence of structural heart disease develop.

WEIGHT

25.8 lb

HOSPITAL NAME

Mountainview AH

REFERRING VET

Dr. Kalivoda



DATE

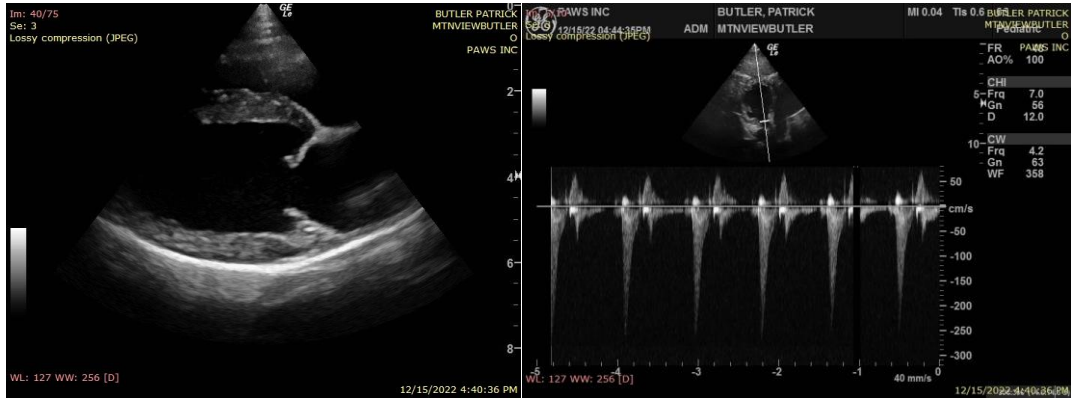
12/16/22

PERFORMED BY:

Loetitia Saint-Jacques, LVT, RVT

INTERPRETED BY

Keith Blass, DVM,
MS, DACVIM
(Cardiology)



The information and recommendations provided are based on the images presented by the referring veterinarian. No evaluation can be communicated regarding pathology that was not visible in the image/video clips provided.

PATIENT

Patrick Butler

Thank you for this referral. If the clinical or image interpretation does not parallel your findings or if I can be of any further assistance please contact me.

Keith Blass, DVM, MS, DACVIM (Cardiology)
KeithBlass@gmail.com
631-804-5754

SPECIES

Canine

BREED

Shiba Inu

SEX

MI

AGE

11 mo

WEIGHT

25.8 lb

HOSPITAL NAME

Mountainview AH

REFERRING VET

Dr. Kalivoda